

# Channel Palpation

By: Wang  
Ju-Yi and Jason  
Robertson

Keywords:  
Palpation,  
diagnostic  
technique,  
acupuncture,  
acupuncture  
technique,  
acupuncture  
theory, channel  
theory.

## Abstract

Channel palpation is a classical diagnostic tool infrequently used in modern acupuncture practice. This article outlines the basic theory and techniques of this useful approach.

## Introduction

Channel palpation was a principal diagnostic tool in early acupuncture therapy. The *Nei Jing* (Inner Classic) and *Nan Jing* (Classic of Difficulties) include descriptions of techniques for palpating the channels to search for nodules and other tissue changes. In the modern clinic there is often a cerebral approach to acupuncture point choice that fails to consider palpatory findings beyond the information provided by the pulse. At the same time, practitioners who are interested in finding ways to integrate palpated findings into their diagnosis often lack a useful theoretical structure to categorise what they are feeling.

This article will first briefly outline the historical antecedents of channel palpation. Then follows a description of what practitioners should feel for when palpating along the course of the channels, and an explanation of how this palpatory information can be interpreted to inform diagnosis and treatment. Finally, a detailed case study is discussed in relation to channel palpation findings.

in Chinese diagnostics. Beginning with the earliest texts, for example, the 73rd and 75th chapters of the *Ling Shu* (Divine Pivot) section of the *Nei Jing* (Inner Classic) (官能 和 刺节真邪)<sup>1</sup> introduce two relevant diagnostic terms. The first is *qiè* (切) and carries a meaning in Chinese of “slicing.” In modern medical terminology the character has come to mean “to press”, as in “to separate the flesh with the tips of one’s fingers.” In modern texts, this character describes the technique for observing the condition of the radial pulse. Of particular interest to the discussion of channel palpation is a second character found in this same section on manual diagnostic techniques. The character is *xún* (循) and carries a meaning of “to go along with.” This second character describes the process of “going along” the course of the channel with the fingers to observe their condition. Thus, while *qiè* is a reference to pulse diagnosis, the character *xún* might be translated as “palpating” the entire channel. Besides introducing the topic of palpating the channels, the 75th chapter of the *Ling Shu* (Divine Pivot) also describes other diagnostic techniques:

*There is reason to believe that channel palpation has historically played a much more prominent role in Chinese diagnostics.*

*“Before using needles one must first scrutinise the channels to determine excess or deficiency. One must separate [the pulse] and palpate. One must press and pluck. Observe how the channel responds and moves before continuing.”*

## Channel palpation in the classics

The technique of channel palpation involves tracing the pathways of the twelve main channels to determine quality of qi and blood flow. Diagnostic palpation is particularly useful in the areas below the elbows and knees, where channel qi develops from the roots at the jing-well points on the fingers and toes, to its inward branching at the he-sea points. Individual channels with compromised function often exhibit physical changes that can be felt relatively easily. These changes include not only more obvious nodules and tenderness, but also weakness of associated muscle groups, generalised increase in muscle tone, or very small, grain-like changes that must be palpated very carefully.

There is reason to believe that channel palpation has historically played a much more prominent role

Thus, the *Nei Jing* (Inner Classic) describes quite clearly that one should not only check the pulse and palpate but also “press and pluck” the channels with the hands as an important part of diagnosis. The text makes another reference to channel palpation in the 20th chapter of the *Su Wen* (Basic Questions) (三部九候论)<sup>2</sup>. In that section, the four techniques of separating, palpating, pressing and plucking are once again described. This chapter also describes a situation where the practitioner discerns *jié* (knots) along the collaterals of the channel. Another example of channel palpation can be found in the 13th difficulty of *Nan Jing* (Classic of Difficulties)<sup>3</sup>. In that chapter, the text emphasises the importance of checking the condition of the forearm from the elbow to the wrist. It specifically describes how the area will feel upon palpation in the presence of various organ disorders.

	Technique	Significance
Generalised hardness and tightness	Palpate all along the channel. Use mid-level pressure. Carefully note which channels are involved. Sensation should be broad.	Acute condition. Compromised function and/or circulation in the channel and/or organ. May be cold in channel.
Deep hardness / nodules	Palpate along channel stopping to circle around smaller changes. Pay attention to shape. Note quality (slippery, soft, fixed etc.).	Accumulation of dampness, phlegm, blood in channel and/or organ. Chronic condition.
	Deep hardness/nodules can be further divided into: Very hard nodules. Defined hard nodules. Hardness in a line (like bamboo). Long stick-like hardness.	
Softness or weakness	Run fingers carefully and lightly along entire course of channel. Note which points are weak.	Qi/yang deficiency.

### Techniques of channel palpation

While traditional pulse palpation is observation of the internal environment through the medium of blood vessels, channel palpation may be thought of as diagnosis through observation of interstitial fluid pathways. Classical physicians believed that the openings and spaces one feels when palpating the channels not only make up a crucial part of physiology, but can also reflect the state of internal organs in the presence of dysfunction. In fact, what we call “the channels” are not actually made of the skin, nerves, tendons, bones, vessels or muscle that we commonly associate with them.<sup>4</sup> Instead, they can be thought of as groups of connective tissue and the fluids moving within them.<sup>5</sup> Like pulse palpation and tongue observation, palpation of these channel pathways provides the practitioner with another tool for verifying and refining a diagnostic hypothesis generated during the interview process.

It is important to note that, when evaluating these changes in a diagnostic context, it is not enough to simply palpate the traditional channel pathways to locate reactive points for needling. The first goal of palpation is not to find points or channels to be treated, but instead to find clues about how the organs are functioning. Diagnosis can only be made after considering the changes noted during palpation in the context of other signs and symptoms. Point or herb selection for treatment must then follow from the diagnosis.

### What to look for

In the clinic, palpation involves moving along the course of the channels with the side of thumb using a sliding technique. Often, the practitioner palpates each channel a few times using varying degrees of pressure. The practitioner should first grasp the

patient’s hand or foot firmly with the right hand then palpate slowly along the course of the channel by moving the side of the thumb along the skin to track all changes. It is important to remember that one is not palpating individual points but entire channels. Movement should be even and fluid without excessive stopping to press individual points. Changes at particular areas of the channel can be confirmed and explored by returning to the channel a second and third time with increasing levels of pressure. It is very important to remember that the “nodules” described in the following pages might be very, very small. These are not the same as lipomas, neuromas or other more obvious fatty deposits.

There are three basic principles to keep in mind when differentiating types of channel change. The first is depth, the second is relative hardness and the third is size and shape of the changes found.

The three general categories of palpable change listed in Chart 1 will each be considered in detail below.

The first and second types of channel change are sometimes difficult to differentiate for the new practitioner.

#### 1. Generalised hardness and tightness

Generalised hardness and tightness is usually felt at a more shallow depth along the channel below the elbows or knees. It is usually less hard and covers a broader area than the other types of hardness described below. In many cases, this is a generalised hypertonicity of the tissues along a relatively large part of a particular channel. It is often seen in cold, damp and/or relatively acute conditions. The channels are affected and movement is compromised, but pathogenic qi has yet to lead to a more serious stagnation of blood or accumulation of phlegm.

Chart 1:  
Three general categories of palpable channel change

Slightly hard nodules with borders that are not clearly defined are also included in this category. This type of nodule might even be quite soft and very small. They will feel less deep than the nodules discussed below, as if they are just below the surface, almost attached to the skin. They are often indicative of a relatively acute situation or one involving muscles, tendons and skin.

Changes that are generalised or relatively shallow and attached to the skin may be thought of as “qi level” while the next type of channel change discussed below can usually be thought of as affecting the “blood level.” Qi level changes involve problems with organ function, in contrast to blood level changes, which correspond to more substantial physical changes in the body. The first type is softer and seen in less serious conditions, while deep hardness often has more definition and involves a more serious pathology.

## 2. Deep hardness and/or nodules

This is the broadest category of channel change. A wide variety of pathological mechanisms can lead to changes of this type, but most are related to stasis of blood, accumulation of phlegm, or the presence of chronic disease. These types of nodules are clearly located below the skin and are less likely to move when the skin moves. Nevertheless, they may not necessarily be deep in the muscle layer. Within the category of deep hardness, there are a few sub-categories:

- a. Very hard nodules often indicate significant cold or blood stagnation. For example, one might find small very hard nodules at Jinmen BL-63 in cases of chronic back pain with blood stasis.
- b. Defined hard nodules that are easily moved and slippery/smooth indicate damp and phlegm. This type of change is often found, for example, on the Spleen channel either around Taibai SP-3 or Yinlingquan SP-9 in damp-phlegm patterns.
- c. Hardness in a line that feels like a piece of bamboo indicates a chronic condition and is often more difficult to treat. The nutritive ability of the fluids is compromised and the palpated change will likely feel a bit bumpy under the thumb. A common area to find this type of change is along the Sanjiao channel between Waiguan SJ-5 and Sanyangluo SJ-8 in autoimmune disorders.
- d. Long stick-like changes that are not bumpy most often indicate an acute condition, generally caused by stagnation of qi. Stick-like lines may also cut perpendicularly across the course of the channel. Changes of this type may arise in the presence of infection or inflammation in areas associated with the channel. For example, there will often be a stick-like change palpated on the Small Intestine channel around Wangu SI-4 or Yanggu SI-5 in cases of acute taiyang type neck pain.

## 3. Soft-weak areas

When palpating the course of an acupuncture channel, there is sometimes a sense that the muscles or fascia have significantly decreased tone. In these cases, certain channels, or even specific points, have a softness that can be felt when running the fingers along the body surface with mild pressure. When palpating channels with softness and weakness, it is more important to note which individual points exhibit softness and to consider the functions and indications of those points.

In general, this is a sign of deficiency. In order to fully understand the nature of the deficiency, one must also consider information gleaned from other diagnostic techniques. However, careful channel palpation can help determine the primary organ affected in cases where a patient presents with what looks like generalised qi and/or yang deficiency or deficiency that seems to involve multiple organs.

## When are changes relevant?

When palpating the body, one will inevitably need to distinguish between what feels “normal” and what feels “pathological”. Patients are of course variable and many different types of change can be felt when one palpates the channels. Over time, however, common patterns of irregularity will begin to emerge. In order to eliminate changes that are not related to pathology, a few guidelines should be kept in mind.

1. Pathological changes should be in a clear line along specific channel pathways.
2. Pathological changes should be connected to symptoms, i.e. they should come and go with the ebb and flow of other symptoms. However, the channel changes may not happen at exactly the same time as symptom presentation and may relate to onset and/or recovery from a particular condition in four main ways:
  - Channel changes happen at the same time as symptoms. Increased intensity of symptoms happens at a similar time to the development of palpable change along the course of the channels. This is the most common pattern in the clinic (roughly 70% of patients).
  - Symptoms precede channel changes. In this situation changes along the channels eventually occur but it may be days or even weeks after the initial symptoms. Changes may also appear very mild in contrast with the presenting symptom pattern. This is seen most often in older, weaker, more deficient patients, who tend to respond slowly to treatment.
  - Channel changes precede clinical symptoms. In this case a constellation of related signs and symptoms may emerge days or weeks after the palpated channel changes have been noted. These are usually patients who are very healthy or those with a tendency to allergies or other autoimmune conditions. Because of the healthy (or hypersensitive) state of their immunity, the channels

themselves show noticeable change during what might be analogous to the “latency period” of their condition.

- Channel changes do not coincide with clinical symptoms. This is a case where there are both symptoms and significant channel change but they do not seem to correspond. It may be a case of chronic disease with no significant channel change, or when symptom diagnosis seems to point to one conclusion while palpation suggests another. This is most often seen in complex disease patterns and diagnosis must involve careful integration of all diagnostic techniques.

Careful records should be kept to watch how the palpated channel changes evolve throughout a course of treatment.

3. Pathological changes should be located bilaterally, although one side may be significantly more affected than the other, especially in acute cases or in cases primarily involving pain.

Changes generally need to meet at least two of the above three conditions in order to be considered significant for channel diagnosis.

Observed changes like lipomas, neuromas, moles, canker sores, pimples, tinea and melanin irregularities (freckles) that do not meet the above conditions are not within the scope of channel diagnosis. Changes of this type are better considered in the context of dermatology in Chinese medicine.

## Case study

45 year old female

**Chief complaint:** allergic dermatitis

### History of presenting illness

The patient presented with dry, red, slightly raised papules. Lesions were focused around the wrists, dorsal surface of the hand, ankles and dorsal surface of the foot, i.e. generally on yangming areas. The lesions were scaly and itchy but did not tend to bleed or become purulent. The condition was chronic, having first appeared seven to eight years previously, and generally appeared in the autumn, continued throughout the winter, and then cleared in the spring. The intensity of outbreaks had worsened in recent years. Use of detergents, soap or warm water irritated the condition - even to the point where she found it necessary to drastically limit hand washing and bathing. Itchiness and redness tended to worsen before the onset of menstruation which was irregular (varying late/early), beginning with a scanty flow for two to three days then followed by relatively normal flow for two more days. The patient's appetite and sleep were normal, while her bowel movements were generally dry, sometimes occurring once every two to three days. The patient also suffered from recurring nosebleeds.

A doctor at a local hospital diagnosed the condition as allergic dermatitis and treated it with a mid-potency topical

corticosteroid. Although steroid treatment provided temporary relief, the condition returned when treatment was discontinued. Another doctor prescribed the herbal formula *Xiao Yao San* (Rambling Powder), which had no effect on the skin problem but did seem to improve the frequency of bowel movements.

### Diagnostic findings

Channel palpation revealed soreness and small, hard nodules that were easily moved on the Lung channel at Kongzui LU-6, and on the Spleen channel at Sanyinjiao SP-6. The area around Yinlingquan SP-9 exhibited tightness and had some swelling. Soft, puffy nodules were found on the Liver channel at Taichong LIV-3. There were some small, shallow stick-like grainy nodules palpated on the Heart channel around both Shaohai HE-3 and Yinxi HE-6. There was also a larger area of hypertonicity of the tissues on the Stomach channel around Fenglong ST-40. The nodules on the taiyin channel were fairly deep, and were generally harder than those found on the Heart, Liver and Stomach channels.

The tongue body was puffy/enlarged and slightly purplish, with a crack in the centre towards the back. The tongue coating was sticky/slippery and white. The pulse was slippery.

### Diagnosis

Taiyin qi disharmony; dysfunction of fluid circulation.

In this case the condition worsened in the autumn and exhibited dryness, both associated with Lung taiyin. The patient's dermatitis was generally located on the yangming surfaces of the arms and legs. In this case, a disharmony of the yin channel was manifesting on its paired yang channel (taiyin condition appearing on the yangming channel). In these types of conditions, it is often appropriate to use yin channel points to treat a yang channel condition. Traditionally, this type of approach is called yang bing qu yin (“choosing yin to treat a yang disease” 阳病取阴). Nevertheless, the chronic nature of this condition and the pattern of menstrual irregularities indicate the presence of blood dryness as a secondary aspect of the condition. The role of channel palpation in determining this diagnosis will be further discussed below.

### Treatment

Treatment focused on regulating taiyin function. As the patient had never received acupuncture before, only four points were used in the first treatment; Chize LU-5 and Yinlingquan SP-9 bilaterally. One-inch needles were used to induce a very gentle, radiating sensation (even technique) on all four points. Subsequent treatments used the original four points with the addition of Yangxi L.I.-5 and Jiexi ST-41 as patches of redness and itchiness were found just distal to both of these moving jing-river points.



## Results

The patient reported a reduction in itching immediately following the first treatment. The following week, the patient reported that the condition had continued to improve and received treatments once weekly for eight weeks. Lesions began to clear first on the lower limbs where redness and scaling also decreased. Healing and reduction of the affected areas on the upper limbs followed. The area around Hegu L.I.-4 was the last to heal, two months after treatment began. Two months after the first treatment, the condition had completely cleared from the yangming surfaces of the arms and legs with one final area on the dorsal surface of the hand remaining, now on the shaoyang channel.

## Addendum

As treatment progressed, the patient reported that she had been having frequent nosebleeds for some time. Palpation revealed tenderness at Tianfu LU-3. There is often a reaction on the taiyin channel at this point when there are abnormalities in nasal vasculature. Bilateral needling of Tianfu LU-3 was added to subsequent treatments, and there was a reported decrease in the frequency of nosebleeds.

## Discussion of channel palpation diagnosis

Before considering the chosen points, it is helpful to return to an analysis of channel palpation. In this case, channel palpation helped to refine and focus both the diagnosis and treatment. As some may have surmised, the initial presentation might easily have led to a diagnosis of blood deficiency with concurrent heat. However, because of the relatively clear involvement of the taiyin Lung and Spleen channels, as determined by channel palpation, a small, focused point prescription was chosen to specifically effect qi dynamic in that channel. Instead of choosing points to strengthen blood and/or clear heat, a pair was chosen which ultimately help to strengthen the synergistic functions of the Spleen and Lung.

However, how might the palpated changes on other channels be considered? In particular, there were a variety of changes palpated on the Liver, Heart and Stomach channels. Most obviously, the changes on those channels were less prominent than the changes palpated on the taiyin channel. Nevertheless, these changes are relevant to creating a clear diagnosis and for helping point selection.

Soft, puffy areas palpated around Taichong LIV-3 indicate a qi level involvement of that organ (see discussion above). As the Liver dredges the pathways of qi, this sign (and also some of the symptoms described by the patient) indicates a component of qi stasis. Small, grainy, stick-like, shallow nodules on the Heart channel further refined the picture. The nature of these changes also point to a qi-level condition. Had the changes been harder or deeper, they might have indicated the presence of a more significant

deficiency and/or stasis of blood. However, it should be pointed out that cases of more severe blood deficiency and stasis affecting the Heart usually present with deeper, broader, and harder nodules or increased muscle tone along the Pericardium channel around Ximen P-4.

Based on the broad picture presented by the signs/symptoms and channel palpation taiyin qi disharmony was diagnosed. This implies not deficiency, but an excess arising from compromised qi dynamic. In particular, the ascending/descending function of the Lung had been compromised; a kind of counterflow qi. The counterflow then affected the taiyin system and led to improper nourishment of the paired yangming channel.

The treatment principle is not tonification, but regulation and movement of qi. The ability of he-sea points to regulate counterflow while strongly moving qi seemed most appropriate. The Chize LU-5/Yinlingquan SP-9 pair is used broadly to re-establish proper qi movement in the taiyin channel. In this specific case, the circulation of fluids and dampness in the spaces around the skin improved and residual heat in the yangming channel cleared as proper nourishment returned.

In many modern acupuncture treatments for dermatology, points are chosen based on function much the same as herbs are chosen in a formula. Points such as Quchi L.I.-11, Hegu L.I.-4, Fengshi GB-31, Sanyinjiao SP-6 or Ganshu BL-18 are generally used to "clear wind" and "benefit the blood" in cases of allergic dermatitis. The approach described above focuses more on regulation of channel and organ function than on clearing wind and/or heat from the blood. In a situation such as this, herbal medicine would be quite effective for clearing, removing and/or tonifying, but acupuncture is best suited for regulation, with the goal of helping the body restore right qi on its own. Often, problems with right qi are not due to deficiency but instead are rooted in a lack of regulated movement of qi and blood in the body. In these cases, acupuncture is often more effective than qi regulating herbal approaches.

## Conclusion

Channel palpation provides a reliable, verifiable and relatively measurable way for practitioners to confirm diagnostic hypotheses derived from more mainstream Chinese medical approaches. Furthermore, because channel palpation provides significant information about the state of organ function, it can help focus diagnosis and treatment. The result, when applied consistently, allows for more precise diagnosis, smaller point prescriptions and, most importantly, better clinical results. The first step for an interested practitioner is to begin carefully palpating changes as described above. Then, over time, the approach will slowly begin to inform and clarify diagnosis. Channel palpation does not involve radically changing one's clinical approach but instead provides a

Figure 1: A deep, hard nodule found along the course of a channel often indicates significant cold or blood stasis. These nodules can be found when pressing relatively hard when going along the course of a channel.

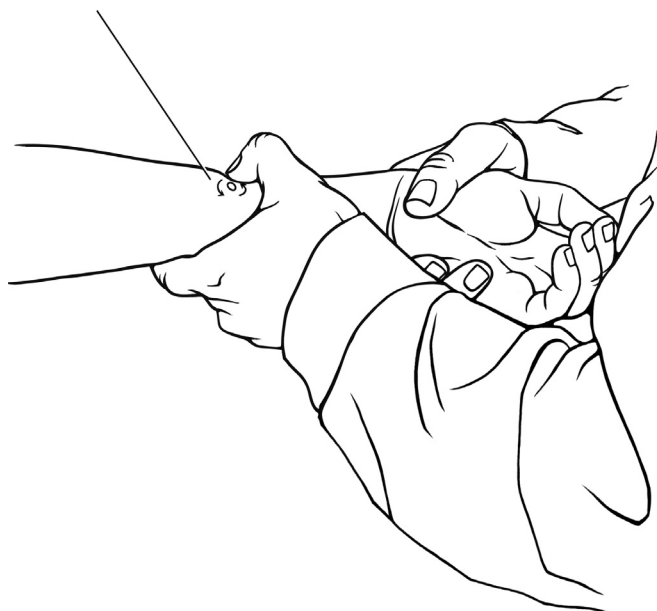


Figure 2: Defined hard nodules that are easily moved and slippery/smooth often indicate damp and phlegm. These nodules can be felt at either deep or shallow levels. They will sometimes feel almost like a small bubble (as opposed to a small mass).

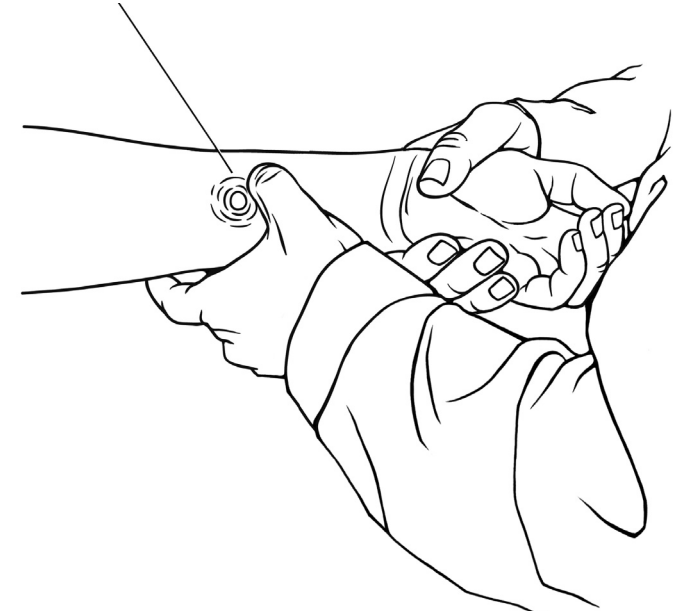


Figure 3: Hardness in a bumpy line that feels like a piece of bamboo indicates a chronic condition. The nutritive ability of the fluids is compromised. These types of changes might also include a series of small nodules in a row along a relatively large portion of the channel.

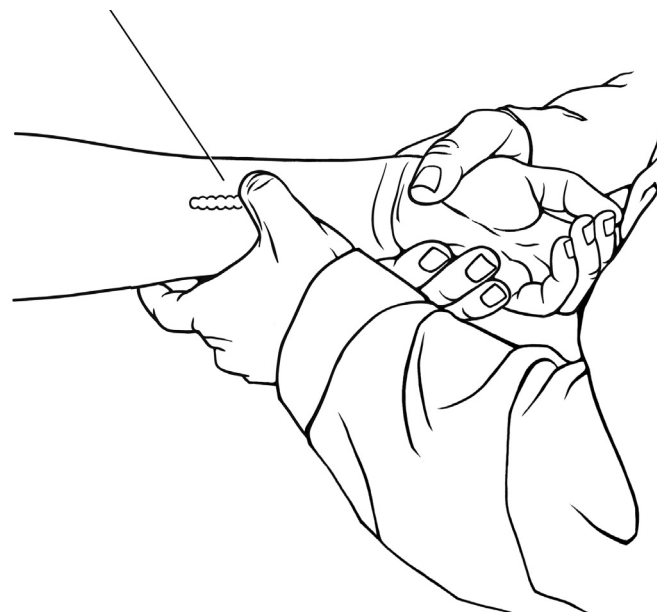
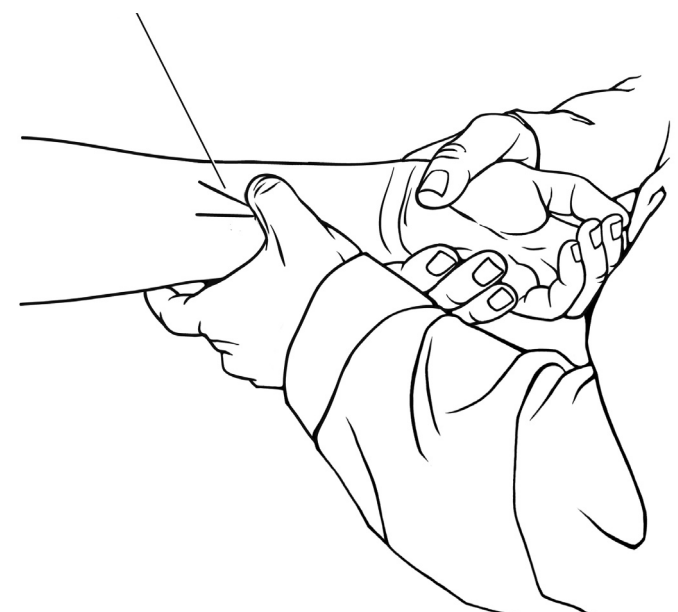


Figure 4: Long stick-like changes that are not bumpy most often indicate an acute condition. The lines may also cut perpendicularly across the course of the channel. There may be infection or inflammation in areas associated with the channel or the associated organ.



useful tool, which can be used in the context of much that has already been learned. ■

*Dr. Wang Ju-Yi (王居易) has practised Chinese medicine for 45 years in Beijing. Formerly the president of the Beijing Kuan Jie Hospital and chief editor of Chinese Acupuncture and Moxibustion (中国针灸 zhōng guó zhēn jiū), Dr. Wang now maintains a private teaching clinic in Beijing.*

*Jason Robertson has studied channel theory and palpation with Dr. Wang for the last 5 years. He currently translates for groups of students at Dr. Wang's Beijing Clinic and has a private practice in Seattle, WA USA.*

*Wang, Ju-Yi & Robertson, Jason Applied Channel Theory in Chinese Medicine: The Lectures of Wang Ju Yi (王居易经络医学讲演录 Wáng jū yì jīng luò yì xué jiǎng yān lù) to be published in 2007 by Eastland Press of Seattle.*

## References and notes

- 1 Nei jing ling shu (Inner Classic Divine Pivot) (内经灵枢), Chapters 73 and 75, 'my translation'.
- 2 Nei jing su wen (Inner Classic Basic Questions) (内经素问), Chapter 20, 'my translation'.
- 3 Nan jing (Classic of Difficulties) (难经), Chapter 13, 'my translation'.
- 4 The concept that acupuncture channels and points do not correspond to obvious anatomical structures is seen, for example in the first chapter of the Ling Shu (Divine Pivot) section of the Nei Jing (Inner Classic) (九针十二原): "... There are 365 of these divisions [points]. Their importance cannot be summarized in just a few words but to ignore their essential role is to invite endless confusion. These things we call 'divisions' are the places where the spirit qi moves, enters and exits. They are something quite different from skin, flesh, tendons and bones."
- 5 For a fascinating parallel to this concept of channels as connective tissue pathways, see Langevin et al. (2002)<sup>7</sup>. In this article, the authors, using ultrasound imaging of interstitial connective tissue, propose that acupuncture channels might be equivalent to connective tissue planes.
- 6 Nei jing ling shu (Inner Classic Divine Pivot) (内经灵枢), Chapter 1, 'my translation'.
- 7 Langevin H M, & Yandow J A (2002). "Relationship of acupuncture points and meridians to connective tissue planes", *The Anatomical Record (New Anatomy)*, 269, 257-265